

## Leukocyte Adhesion Defect Type 1. Reporting Patient Series and their Survival Without Bone Marrow Transplantation.

نقص جزيئات الالتصاق لخلايا الدم البيضاء / النوع الأول

Omar Abuzaitoun, Husni Maqbuol, Hasan Fitian, Hikamt Al Sae'ed

Faculty of Medicine. An-Najah National University. Nablus. Palestine.

E-Mail: oabuzaitoun@pol.net

Received: (21/12/2004), Accepted: (28/8/2005)

### Abstract:

The survival of patients suffering from severe LADI is discussed in this paper. The approach is to do bone marrow transplantation as soon as possible, however, we report 4 patients suffering from severe LADI, who did not have bone marrow transplantation. We report the favorable outcome with conservative treatment (prophylactic antibiotics)

### ملخص

إن المرضى الذين يعانون من نقص شديد في جزيئات الالتصاق على خلايا البيضاء عادة ما يحتاجون إلى زراعة نقي العظمى للعلاج. نحن نقدم أربع حالات تم تشخيصها في مدينة نابلس، ولم تتم عملية زرع نقي النخاع لهم. وقد كانت النتيجة مرضية باستعمال العلاجات الوقائية فقط (مضادات حيوية وقائية)

**Introduction:**

Leukocyte adhesion defect type 1 (LAD 1) is a rare primary immune deficiency disease. The true incidence of this disease is not known. It is believed to occur approximately 1: 1000 000 life birth.

Patients with LAD1 were initially described as having severe recurrent infections beginning at early infancy <sup>(1,2)</sup>. They are also reported to have gingivitis and bad wound healing. If undiagnosed, or diagnosed late, they die in the first year of life.

Patients with LAD1 fail to express the adhesion molecules (CD11-CD18) on the surface of the neutrophils rendering the neutrophils unable to migrate into sites of infections, persistent neutrophilia, defective neutrophil chemo taxis, and impaired phagocytosis of particles <sup>(3)</sup>. Antibody-dependent cytotoxicity and cytotoxic T cell functions are also abnormal <sup>(4)</sup>.

The severity of the disease is related to the amount of expressed CD11-CD18 complex protein on the cell surface. Patients who express less than 1% of CD11-CD18 complex on the cell surface have severe form of LAD1 and bone marrow transplantation is usually recommended <sup>(5)</sup>. Patients who express 1-30% of normal value of CD11-CD18 have milder presentation <sup>(4)</sup> and antibiotic prophylaxis may play a role in their survival but bone marrow transplantation is an option if they have recurrent severe infections, though this is not a fully defined treatment option. We report our experience in patients with severe form of LAD1 in which conservative management (no bone marrow transplantation) was followed and describe their clinical course. We found so far that the conservative option has reasonable results especially when early diagnosis is made. Limited resources played an important role in our clinical decision-making.

**Patients, clinical presentations and their families.**

Our practice is in an area in which consanguinity is common. The parents in the first family (family A) are first-degree relatives (as well as their parents). In early 90s, this family had 3 boys who died without diagnosis in the first few months in life. After the presentation of the first case to our department, the medical records of these 3 patients were reviewed and showed that all these boys had very high neutrophil count (WBC 100,000 cell per mm<sup>3</sup>, neutrophils : up to 75%). One of these patients had Klebsilla sepsis. Another patient had a severe gum and palate inflammatory process that caused perforation of the hard palate into the maxillary sinus. Diagnosis was not confirmed in these 3 cases, but most likely they had had severe form of LAD1.

The parents in family B are 1<sup>st</sup> degree relatives of the parents in family A. We diagnosed 2 male siblings with severe LAD1 in family A and 2 female siblings with severe LAD1 in family B.

***The first patient ( FAMILY A, 1):*** A newborn presented with leukocytosis without fever at the age of 20 days. His WBC was 29.000 cells per mm<sup>3</sup>, 70% were neutrophils. He was a product of full term pregnancy and normal spontaneous vaginal delivery. His birth weight, length and head circumference were appropriate for age. Due to given family history, septic work up was performed and the patient was started on ampicillin and gentamicin as a case of potential neonatal sepsis. Ampicillin was administered at a dose of 100 mg/kg/day and gentamicin was administered at a dose of 7.5 mg/kg/day. However no organisms were isolated. His elevated white cell count and neutrophilia continued with no signs of infections (WBC 40.000 cell/mm<sup>3</sup>). At the age of 2 months he developed cellulites in his left axilla . Culture from this lesion grew pseudomonas species. He responded to amikacin at a dose of 30mg/kg/day intravenously. CD11 and CD18 complex were performed in Medlab Laboratory (Nablus) and in Rambam Medical Center Laboratory (Haifa) and the results were as follows

CD11a 1% of normal.

CD11b zero% of normal.

CD18 zero % of normal.

He was started on prophylaxis antibiotics (cloxacillin 40mg/kg/day given orally twice daily and cotrimexasole at 10 mg/kg/day of trimethoprim given orally for 3 days/ week). Since the age of 2 months until now (5 years of age) the clinical course of the patient is summarized as follows:

- 1- Acute otitis media. 6 reported episodes in the first year of life. The frequency of otitis media decreased in the 2<sup>nd</sup> year of life and became very infrequent in the 3<sup>rd</sup> year of life. Response to antibiotics was reasonable.
- 2- One episode of viral croup at the age of 1 year. He recovered with no complications.
- 3- Anemia at the age of 2 years. Hemoglobin was 7.8 gm/dl. This anemia was not fully investigated. Most likely it is caused by recurrent infections (anemia of chronic disease) and cotrimexasole used on chronic basis.
- 4- Fungal esophagitis at the age of 3 years. Diagnosis was made on clinical presentation of refusal to feed (and later refusal to drink water) for one week supported by findings on contrast study (barium upper GI study). Endoscopic studies were not performed. Most likely this inflammation was caused by *Candida* species. It responded to intra-venous amphotericin B at a dose of 1 mg/ kg/ day. Recovery was complete with no complication.
- 5- One episode of *E coli* urinary tract infection at the age of 3 years.
- 6- Psoriasis like skin rash. Skin biopsy from this lesion confirmed psoriform dermatitis. (Figures 1 and 2). Absence of neutrophils in the lesion was noted.

- 7- WBC remained in the range of 30.000-50.000 cell/mm<sup>3</sup>, mostly neutrophils.
- 8- Cellulites on both feet at the age of 5 years. It responded to intravenous cefotaxime, gentamicine and intravenous vancomycine.
- 9- Severe gum disease that started at the age of 4 years. Required gingival curettage and finally extraction of all the deciduas teeth. Prophylactic intravenous ampicillin and gentamicin before and after the procedure were used. (Conventional doses).
- 10- Peri-anal abscess at the age of 1 year responded to saline sitz bath.
- 11- The patient was hospitalized with fever several times; no organisms were isolated from the blood, urine or CSF. We used to hospitalize him for any febrile illness especially in the first year of life.
- 12- Delayed and poor wound healing with scar formation.
- 13- Abscess in the inner aspect of the thigh at the age of 5years. It responded to intravenous vancomycine and ceftazidime.
- 14- Growth and development were normal.
- 15- Separation of the umbalical cord was not delayed. (Triple dye was not applied).
- 16- He tolerated vaccination very well. (See discussion).

At the age of 2 years flowcytometry was repeated in the same laboratories mentioned with upgrading challenge to the neutrophils, results as follows

Without upgrading:

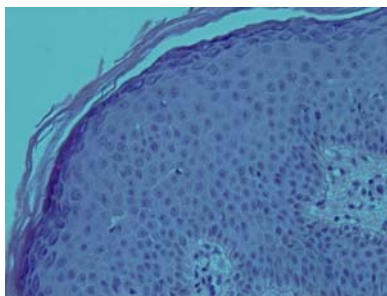
CD11a 1%.

CD11b and CD18 zero %.

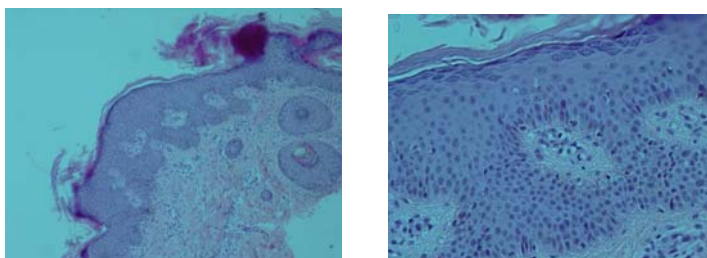
With upgrating CD11 a and b and CD 18 were 1-2%. This minor increment in the expression of these adhesion molecules is probably insignificant.

The patient continues on prophylactic oral antibiotics. He lives with his family; the frequency of his illnesses is getting less with time. Response to the used antibiotics for any given illness used to be good and reasonable.

The development of psoriform skin lesions in this patient was not thoroughly investigated; it is probably due to impaired clearance of immune complexes in these patients.



*Figure(1) Psoriform skin lesion in a Patient suffering from LAD1.(patient 1, family A)*



*Figure(2) Psoriform skin lesion in the same patient mentioned in figure 1*

**The second patient (FAMILY A, 2)**

This patient is a brother to the first patient. He was delivered by normal spontaneous vaginal delivery at term. His birth weight, length and head circumference were appropriate for age. He presented to our department at the age of 3 weeks with severe omphalitis.

At the time of writing this report he was 2 years old. He is a male patient; he had WBC of 20.000 cell/mm<sup>3</sup> at birth.

Flow cytometry was performed ( same laboratories mentioned above) at the age of one month with the following results

CD11 a and CD11 b were zero% of normal.

CD18 was zero % of normal.

He was maintained on antibiotics as his brother.

His clinical course can be summarized as follows:

- 1- Severe omphalitis at the age of 3 weeks. It responded to intravenous vancomycine and ceftazidime with no complications.
- 2- Separation of the umbalical cord was not delayed. (Triple dye was not applied)
- 3- Severe necrotic peri anal cellulites at the age 7 months. This was extensive involving a wide area of the perineum and gluteal area. It responded to salt-water sitz bath.
- 4- Several episodes of otitis media especially in the first year of life. Response to oral antibiotics was reasonable.
- 5- So far he has no gum disease. (His brother developed the gum disease at the age of 4 years).
- 6- Delayed wound healing and scar formation.
- 7- Anemia. This anemia was not fully investigated. Most likely it is caused by recurrent infections and cotrimexasole used on chronic basis.

- 8- Scalp cellulites associated with high fever at age of 2 years, required intravenous antibiotics to recover.
- 9- Normal growth and development.
- 10- He tolerated vaccination well with no complications. (See discussion)

The patients responds to antibiotics quicker and he seems to get less frequent illnesses than his brother, this is likely due to more compliance from the family to antibiotic prophylaxis (cloxacillin 40mg/kg/day given orally twice daily and cotrimexasole at 10 mg/kg/day of trimethoprim given orally for 3 days/ week). Especially in the first year of life, we used to admit him to the hospital for intravenous antibiotics for almost any febrile illness.

### **The 3<sup>rd</sup> patient (FAMILY B, 1)**

Female patient, her parents are first-degree relatives to the parents in family A. (Figure 5).

She was the first baby to this family. She was delivered by normal vaginal delivery at term. Her birth weight, head circumference and length were all appropriate for age. Her initial presentation was with septic shock and bad omphalitis. She responded to intravenous vancomycine and ceftazidime. She was placed on prophylactic antibiotics as the previous 2 patients.

CD11 a and b and CD18 expression at the age of 8 weeks ( same laboratories ) were zero %.

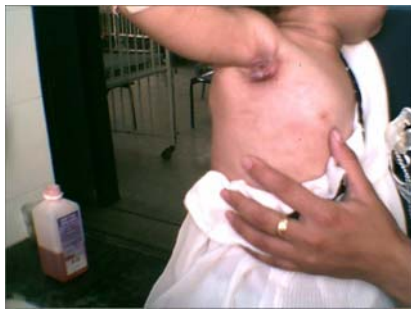CD 11 a and b and CD18 complex were repeated in different laboratory ( Jordan University Hospital Laboratories ) at the age of 1 year, they were also zero%.

Average WBC is 40.000 cell / mm<sup>3</sup>. Her age at the time of writing this report was 3 years.

Her clinical course can be summarized as follows:



- 1- Septic shock and severe omphalitis at the age of one week. Her response to antibiotics was very reasonable.
- 2- Separation of the umbilical cord was not delayed. (Triple dye was not applied).
- 3- Necrotic and prolonged skin cellulitis at the age of 2 months, caused by pseudomonas species.
- 4- Recurrent labialis, likely viral. This lesion was noticed to occur frequently in this patient. It is vesicular in nature and most of the time associated with fever. The etiology was not confirmed.
- 5- Recurrent impetigo.
- 6- Anemia, which was similar to the anemia in the first two cases.
- 7- Hospitalized several times with fever, no organisms were isolated.
- 8- Necrotic cellulites, left axilla age of 2 years, required hospitalization for IV antibiotics and dressing.
- 9- No gum disease so far.
- 10- Normal growth and development.
- 11- Otitis media. Several reported episodes. All responded well to antibiotics.
- 12- Delayed wound healing and scar formation.



*figure (3) Skin infection with cellulites in a patient with severe LAD1. This lesion grew pseudomonas species.*

She is on antibiotic prophylaxis (cloxacillin 40mg/kg/day given orally twice daily and cotrimexasole at 10 mg/kg/day of trimethoprim given orally for 3 days/ week) As she is getting older; the frequency of illnesses is getting less. She lives almost a normal life.

#### **The 4<sup>th</sup> patient (FAMILY B, 2)**

A female patient, who is a sister of the 3<sup>rd</sup> patient in this group. She was delivered by normal spontaneous vaginal delivery at term. She was normal at birth and physical parameters were appropriate for age. She presented first with acute otitis media at the age of 4 weeks. She was hospitalized for this minor illness, but the patient was discharged against medical advice. The infection in the middle ear spread into mastoid air cells and to the adjacent soft tissues. Her initial WBC was 40,000 cell / mm<sup>3</sup>. Despite potent and parenteral antibiotics the infection progressed and later died with sepsis. Pseudomonas species was isolated from ear drainage. She developed anemia early in her life (age of 2 months). Her hemoglobin was 5 gm/dl. The cause of anemia was not clear.

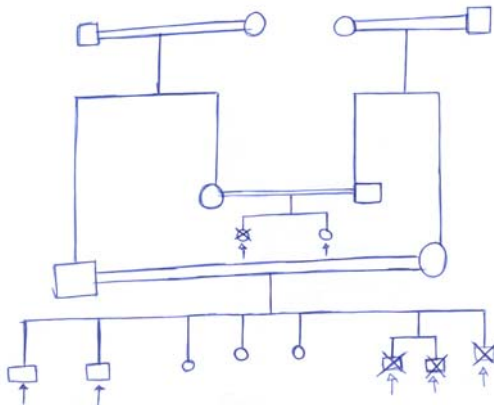


Figure (4) Head CT scan of patient # 4 with otitis media and infection of nearby tissue.

Though the diagnosis of this patient was not confirmed. Her clinical course is strongly suggestive of severe LAD1.



Figure (5) Head CT scan of patient # 4.



Figure(5). Family pedigree of the patients. Double parallel line indicates consanguineous marriage. The circle symbol stands for female, the square symbol stands for male. The arrow indicates that this person is affected with LAD1. >< sign indicates that this patient died with LAD1.

## Discussion

Inherited diseases (like these patients with LAD1) are more common in the middle- east than the other parts of the world. This is due to consanguinity in marriages. However, finding a matched bone marrow donor for these patients becomes much more probable and the success rate of transplantation has a higher potential. We could not provide bone marrow transplantation to our patients as this type of medical care is not available locally and the difficulties that were implemented on the patients in the transportation due to unstable political situation. We were obligated to follow the conservative management.

The frequency of hospitalization was noticed to get less as patients are getting older. Though, all these patients developed several life-threatening illnesses. Compliance to prophylactic antibiotics plays very important role in the outcome. Prompt administration of antibiotics against staphylococci and pseudomonas species played also a role in the good outcome.

Anemia was reported in the 4 cases. It is mostly due chronic disease and use of cotrimexasole on chronic basis. Other typical features of LAD1 were delayed wound healing, scar formation, gum disease, candidal esophagitis and severe omphalitis. However, delayed separation of the cord was not reported in our patients. One patient developed psoriasis like skin rash.

We believe that this series of patients provides an example of favorable outcome with conservative approach.

Prophylactic antibiotics used are cloxacillin and cotrimexasol. Vaccinations that were avoided are BCG (the tuberculosis vaccine) and oral poliomyelitis vaccine (OPV). The BCG is especially contraindicated in these patients. The patients were vaccinated with measles, mumps and rubella vaccine (MMR), measles, and Diphtheria, tetanus, pertussis vaccine (DTP), Hepatitis B and killed poliomyelitis vaccine (IPV) as per the ministry of health protocol. Hemophilus influenza type B vaccine was provided for these patients on the recommended age. The available Pneumococcal vaccine was provided at age of 2 years. No complications

of the vaccinations were reported in these patients including MMR and measles vaccines. Chickenpox vaccine was not given.

Regarding the patient that died (FAMILY B, 2). We believe that her demise was due to spread of infections intra-cranially. Compliance to treatment played a role as mentioned before. Her condition was unstable and will be likely a poor candidate for bone marrow transplantation.

This series shows that early diagnosis of LAD1 plays a favorable role in good out come. All our patients were diagnosed before the age of 2 months. Also we believe that patients suffering from LAD 1 with expression of CD11 a,b and CD18 of less than 1% may survive without bone marrow transplantation. The medical literature support bone marrow transplantation in severe cases of LAD 1<sup>(5,6,7,8)</sup>, to our knowledge, this is the 1<sup>st</sup> series describing a reasonable out come with out bone marrow transplantation. 3 of these patients survived infancy. The first case is now 5 years. The second case is 3 years and the 3<sup>rd</sup> patient is 2 years old.

#### References:

- 1- Crowley, CA., Curnutte, JT., Rosin, RE., Andre-Schwartz, J., Gallin, JI., Klempner, M., Snyderman, R., Southwick, FS., Stossel, TP., Babior, BM.: An inherited abnormality of neutrophil adhesion: its genetic transmission and its association with a missing protein. *N Engl J Med* 302:1163-1168, 1980
- 2- Bowen, TJ., Ochs, HD., Altman, LC., Price, TH., Van Epps, DE., Brautigan, DL., Rosin, RE., Perkins, WD., Babior, BM., Klebanoff, SJ., Wedgewood, RJ.: Severe recurrent bacterial infections associated with defective adherence and chemotaxis in two patients with neutrophil deficit in a cell associated glycoprotein. *J Pediatr* 101:932-939, 1982

- 3- Todd, RF., Freyer, DR.: The CD11/CD18 leukocyte glycoprotein deficiency. *Hematology/Oncology Clinics of North America* 2:13-31, 1988
- 4- Anderson, DS., Schmalsteig, FC., Finegold, MJ., Miller, LJ., Kohl, S., Tosi, MF., Jacobs, RL., Waldrop, TC., Goldman, AS., Shearer, WT., Springer, TA.: The severe and moderate phenotypes of heritable Mac-1, LFA-1 deficiency: their quantitative definition and relation to leukocyte dysfunction and clinical features. *J Infect Dis* 152:668-689, 1985
- 5- Thomas, C., Le, Deist, F., Cavazzana-Calvo, M., Benkerrou, M., Haddad, E., Blanche, S., Hartmann, W., Friedrich, W., Fischer, A.: Results of allogeneic bone marrow transplantation in patients with leukocyte adhesion deficiency. *Blood* 86:1629-1635, 1995
- 6- Mancias, C., Infante, AJ., Kamani, NR.: Matched unrelated donor bone marrow transplantation in leukocyte adhesion deficiency. *Bone marrow transplant* 1999 Dec; 24(11):1261-3
- 7- Farina, NJ., Duval, M., Wagner, E., Chamagne, J., Lapointe, N., Barrette, S., Tapiero, B., Busque, L., Champagne, MA.: Unrelated bone marrow transplantation for leukocyte adhesion deficiency. *Bone marrow transplant* 2002-Dec;30(12):979-81
- 8- Hattori, H., Tsuruta, S., Horikoshi, Y., Amano, K., Takashima, Y., Shakashuta, K., Mimaya, J., Kimura, M., Yshida, T.: Successful human leukocyte antigen one antigen mismatched related bone marrow transplantation in a 6 year old boy with leukocyte adhesion deficiency syndrome: *Pediatr Int.* 2001 Jun; 43(3):306-309